



**RESENTING CLINICAL SIGNS**

**DATE** History: In hospital for ADR, suspect pancreatitis. New murmur and possible arrhythmia on PE.

**ECHOCARDIOGRAPHIC FINDINGS**

8/27/21 2D, M-mode, and Doppler study.

**PERFORMED BY:** Left atrial size is normal. The mitral valve leaflets are mildly thickened, and there is prolapse of the anterior leaflet. There is Doppler evidence of mitral regurgitation present. Left ventricular dimensions are normal. Left ventricular systolic function is hyperdynamic. The aorta and aortic valve are normal. Right atrial and right ventricular dimensions are normal. The tricuspid valve appears normal, though trace tricuspid regurgitation is present. The pulmonary artery and pulmonic valve are normal. No shunting lesions are visualized. No pericardial effusion or cardiac masses are seen.

Dr. Meredith Swart

**INTERPRETED BY**

Keith Blass, DVM,  
MS, DACVIM  
(Cardiology)

LVIDd - 20.8 mm  
LVIDs - 11.3 mm  
FS - 45.7%  
LVOT - 1.23 m/s  
RVOT - 0.76 m/s

**PATIENT**

Lola Orender

**ASSESSMENT/RECOMMENDATIONS**

Degenerative mitral valve disease

**SPECIES**

Canine

This examination demonstrates regurgitation of blood across Lola's mitral valve resulting from degenerative valve disease. The hemodynamic effects of the regurgitation appear to be mild, as Lola does not have secondary dilation of either of her left heart chambers, and her left ventricular systolic function is well-preserved. As such, Lola's mitral valve disease appears to be well-compensated, and her current risk for the development of clinical signs secondary to her disease, such as coughing, exercise intolerance, syncope, and labored breathing, appears to be low.

**BREED**

Chihuahua Mix

An ECG is recommended to further evaluate Lola's irregular heart rhythm.

**SEX**

No therapy is recommended at this stage of Lola's mitral valve disease.

**FS**

A recheck echocardiogram is recommended in ~6 months to monitor for disease progression.

**AGE**

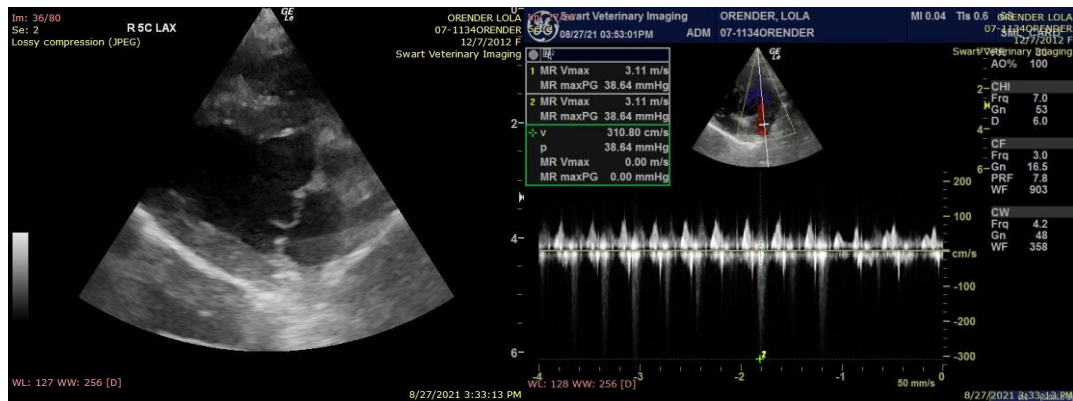
8 y

**WEIGHT**

6 lb

**HOSPITAL NAME**

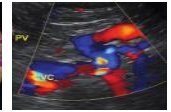
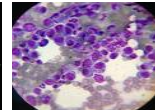
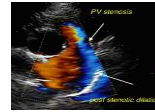
Swart Veterinary  
Imaging



**REFERRING VET**

Dr. Swart

The information and recommendations provided are based on the images presented by the referring veterinarian. No evaluation can be communicated regarding pathology that was not



visible in the image/video clips provided.

**DATE**

8/27/21

Thank you for this referral. If the clinical or image interpretation does not parallel your findings or if I can be of any further assistance please contact me.

**PERFORMED BY:**

**Keith Blass, DVM, MS, DACVIM (Cardiology)**  
KeithBlass@gmail.com  
631-804-5754

Dr. Meredith Swart

**INTERPRETED BY**

Keith Blass, DVM,  
MS, DACVIM  
(Cardiology)

**PATIENT**

Lola Orender

**SPECIES**

Canine

**BREED**

Chihuahua Mix

**SEX**

FS

**AGE**

8 y

**WEIGHT**

6 lb

**HOSPITAL NAME**

Swart Veterinary  
Imaging

**REFERRING VET**

Dr. Swart